

CLINICAL X-RAY STUDY OF COMPLICATIONS OF DENTAL IMPLANTATION AND SINUSLIFTING IN PATIENTS WITH MAXILLAR SINUSITIS

Ilkhom Ikromovich Khasanov - assistant of the Department of Dentistry of Samarkand State Medical Institute, e-mail: mr.ilkhom.khasanov@mail.ru

Kakhramon Erkinovich Shomurodov - Dean of the Faculty of Pediatric Dentistry, Head of the Department of Oral and Maxillofacial Surgery, TSDI, Doctor of Medical Sciences, Associate Professor. e-mail: kahramon_sh@mail.ru

Alisher Isamiddinovich Khazratov - Head of the department of magistracy, Head of the Department of Oral surgery and Implantology, Samarkand State Medical Institute, Doctor of Philosophy of Medical Sciences. e-mail: alisherxazatov@mail.ru

Samarkand State Medical Institute, Tashkent State Dental Institute

Relevance of the topic

Dental implantation takes an important place in the rehabilitation of patients with partial and complete absence of teeth. Currently, the planning of dental implantation methods and approaches to prosthetics are based on a clinical, X-ray and imaging examination, which makes it possible to simulate the prognosis and outcome of treatment at the final stage of manufacturing a prosthesis based on implants (Ivanov S.Yu. et al. 2004; Kulakov JI.A., Robustova T.G., Nerobeev L.I. 2010; Blanchet E., Lucchini JR, Jenny R., 2004; Widmann G., Stoffher R., Bale R., 2009).

Dentist surgeons in situations of loss of a group of chewing teeth in the upper jaw are faced with an insufficient amount and quality of bone, which is essential for surgical interventions.

Currently, methods for correcting the height of the alveolar process and the bottom of the maxillary sinus with the use of operations - sinus lifting have become widespread (Nikitin A.A. et al., 1998; Losev F.F., 2000; Ivanov S.Yu. et al., 2000; Robustova T.G., 2003 Ushakov A.A., 2010; Kharlamov A.A., 2011, etc.).

Nevertheless, the problem of preparing the implantation bed, associated with atrophy of the alveolar process, remains relevant.

Despite all the significant introduction of dental implantation into the practice of dental practice, the number of complications increases at the stages of patient rehabilitation. Thus, the number of cases of patient dissatisfaction with the quality of treatment, inconsistency with the proposed effect and the expected results is increasing (Kulakov A.A. 1997; Gvetadze R.Sh. 2006; Robustova T.G. 2003; Pashinyan G.A. 2000; Rabinovich S.A. 2001; Ushakov A.I. 2002; Babbush S. 2001; Misch CE 1999).

The reasons that inevitably lead to complications and a decrease in the quality of dental implantation are: poor professional competence of a specialist; insufficient material and technical base of medical institutions, namely the outpatient link and private clinics; material interest of the doctor in the use of expensive treatment, even in doubtful cases (Losev F.F. 2006., Drobyshev A.Yu. 2008, Ushakov R.V. 2005). However, the researchers also recognized the fact of objective reasons, namely the imperfection and incomplete informativeness of clinical and instrumental-laboratory methods of local examination of patients (Vasiliev A.Yu., Ivanov S.Yu., 2008, Arzhantsev A.P. 2008., Jacobs K. 2002, Edinger D. 2002).

All of the above led to the implementation of this study.

Objective: to improve the efficiency of dental implantation in the distal upper jaw in patients with sinusitis.

Materials and research methods

We examined 56 patients who underwent implant treatment for the edentulousness of the lateral group of teeth in the upper jaw in the period from 2018 to 2019 at the clinical base of the Department of Maxillofacial Surgery of SamMI. Patients aged 44 to 59 years old, without severe somatic pathology, of whom 30 women (53%), 26 men (47%). According to the results of clinical examination, the patients were divided into three groups:

Group 1 (observation group) - 32 patients with edentulous and inflammatory changes in the maxillary sinus, who had previously undergone surgical debridement of the sinus before implant treatment. Indications for surgical debridement were: acute and chronic sinusitis in the acute phase, sinus cysts and polyps, diffuse (total / subtotal) mucosal hyperplasias, foreign and fungal sinus bodies.

Group 2 (comparison group) - 24 patients with edentulousness, not accompanied by pathological changes in the maxillary sinus. Patients in this group underwent implant treatment without any sinusitis treatment.

The research methods were: clinical examination of patients, radiation diagnostic methods, methods of surgical debridement of the maxillary sinus and methods of dental implantation. The main clinical study included traditional methods such as: questioning, examination, palpation, percussion and probing. When examining the oral cavity, special attention was paid to the study of the shape and degree of atrophy of the alveolar processes, the length of the dentition defect that needs to be filled with implants, the distance from the crest of the alveolar process of the upper jaw to the occlusal plane (Figure 1).

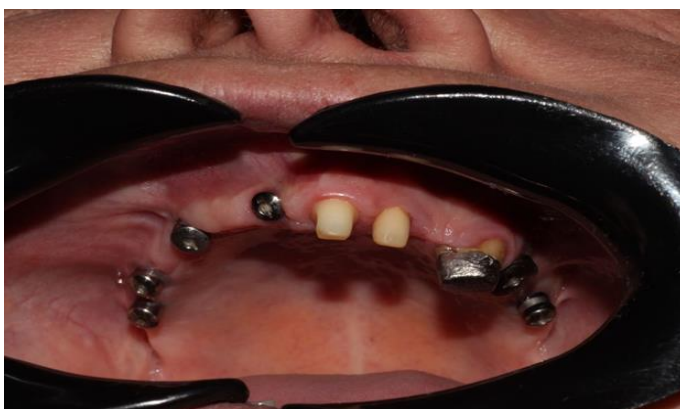

Figure: 1. Examination of the oral cavity. Lack of teeth. View from the occlusal surface. Installed gingiva formers in the area of 11-13-15-16 and 25-27 teeth.

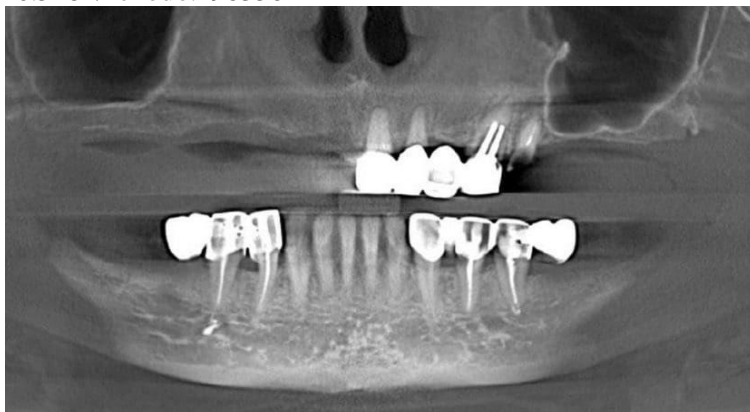


Figure: 2. Cone-beam computed tomography of the upper and lower jaw. Missing teeth in the upper and lower jaw. Atrophy of the alveolar process along the height of the distal upper jaw.

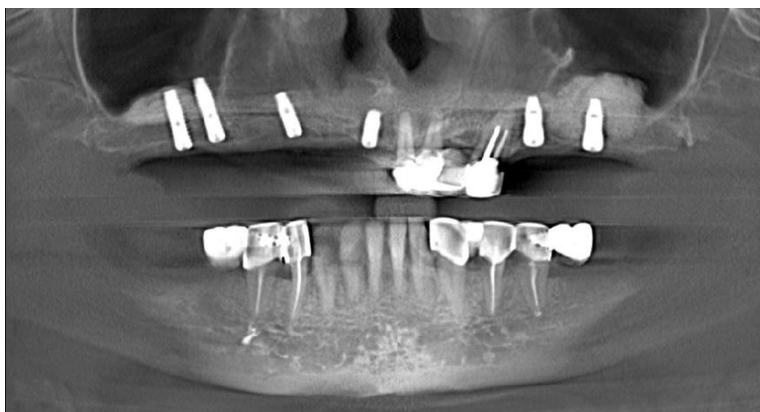


Figure: 3. Cone-beam computed tomography of the upper and lower jaw. In the distal parts of the upper jaw, a sinus lifting operation with bone augmentation was performed. DIO implants were installed in the areas 11-13-15-16 and 25-27.

The algorithm of radiation examination included the performance of orthopantomography (OPTG), multislice computed tomography (MSCT) or cone beam computed tomography (CBCT).

Orthopantomograms were obtained on an X800 R100 CP orthopantomograph (J. Morita, Japan) with the following parameters: 70 kV, 8 mA, exposure 15 sec. MSCT were performed on a GE Lightspeed plus tomograph (General Electric, USA) under the following conditions 80-140 kV , 10 mA, scanning time 120 sec, slice thickness 0.625 mm.

CBCT was performed on a digital cephalometric X-ray apparatus with the function of a computer tomograph "X800 R100 CP" (J. Morita, Japan) under the following conditions 40-90 kV, 2-10 mA, tomography time 15 sec, slice thickness 0.1 - 0.2 mm.

Surgical interventions were performed in the private clinic "DOCTOR KHASANOV STOMA SERVICE".

Dental implantation and sinus lifting methods

For adentia of the lateral group of teeth in the upper jaw, implant treatment was carried out according to 3 protocol options (Table 1)

Table 1

Distribution of patients by methods of surgery, number performed operations and installed dental implants

Implantation		Sinus lifting simultaneous Implantation		Sinus lifting From Delayed Implantation
Number operations	Number Implant	Number operations	Number Implant	Number Operations
0	0	12	48	22

Observation group					
Comparison group	3	8	18	54	6

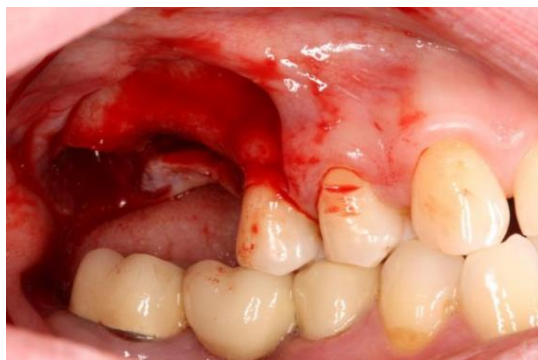Dental implantation was performed at an alveolar ridge height of 8 mm or more according to the standard protocol recommended for each specific dental implantation system.

We used the Impro, Osstem, DIO systems.

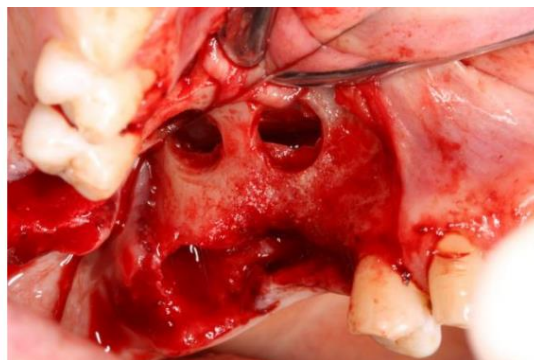
Sinus lifting with simultaneous implantation was performed at a height of 3 to 8mm by two methods:

Closed sinus lifting - with insufficient ridge height up to 2 mm. Through the formed bed for the dental implant, using osteotomes, the cortical plate was broken, the sinus mucosa was lifted, followed by the introduction of xenogenic osteoplastic material under the mucous membrane, a dental implant was installed (Ole T. Jensen 2006).

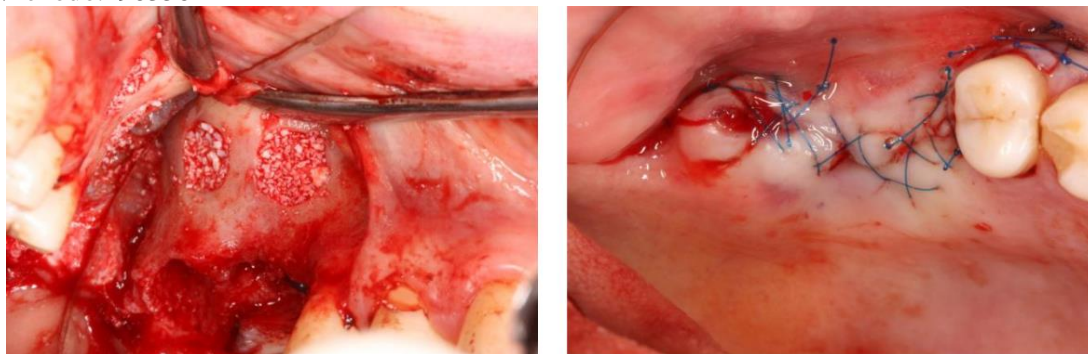
In all other cases, open sinus lifting with one-stage dental implantation was performed using the modified Tatum technique (1986). A bony window was formed along the anterolateral wall of the sinus, with the help of special curettes, the sinus mucosa was lifted, bone-plastic xenogenic material was introduced, and dental implants were installed (Figure 4).



a



b



c

d

Figure: 4. Stages of open sinus lifting in patient A., 34 years old: a - mucosal periosteal flap is detached; b - bony windows were formed and the mucous membrane of the VSP was lifted; c - osteoplastic material was introduced, dental implants were installed; d - the flap is laid in place, fixed with continuous and interrupted sutures

In the case of perforation of the mucous membrane, if its size did not exceed 5 mm, it was isolated by a collagen membrane, bone-grafting material was introduced, and the installation of implants was postponed to the next stage.

Sinus lift with delayed implantation was also performed according to the modified Tatum technique (1986) at the height of the alveolar ridge at a height of less than 4 mm.

Statistical processing of the obtained data was carried out using the STATIC 7 statistical analysis software package on a Pentium 4 personal computer with Microsoft software.

Comparative analysis of the indicators obtained during the examination and treatment of patients was carried out using the Student's t-test with a level of reliability $p \leq 0.05$ generally accepted for medical research.

Results and its discussion

During the study, it was noted that in patients who underwent only dental implantation, in the early postoperative period, the only complication was suture failure (3 patients).

In patients who underwent sinus lifting with one-stage implantation, suture failure was noted in five cases, soft tissue hematoma in eight patients, and in five cases signs of serous rhinosinusitis were detected, which were successfully stopped by general and local anti-inflammatory and antibacterial therapy.

In 5 out of 11 patients who had perforation during sinus lifting with delayed dental implantation, the clinical picture of acute maxillary sinusitis developed, in 3 of them in the form of purulent sinusitis, with involvement of osteoplastic material in the process. In two other cases, signs of serous sinusitis were noted, but one of the In these patients, serous sinusitis was accompanied by the migration of osteoplastic material into the sinus lumen. Divergence of sutures in this group of patients was noted in two cases and was accompanied by suppuration of the surgical wound with involvement of bone-plastic material in the process.

Hematoma was noted in 5 patients.

After three months, patients who underwent dental implantation without sinus lifting, according to the standard prosthetics protocol on dental implants, received healing abutments. When installing the formers, attention was paid to the condition of the soft tissues, in particular to the amount of keratinized and attached gums, its biotype, presence or absence of inflammation.

The level of bone tissue relative to the cervical area of the implant was assessed by X-ray; resorption of bone tissue before the first thread was considered acceptable. The stability of the implant was assessed by a 35N load on the reverse torque. No pathology was revealed in any of the patients, and after two they were referred for further prosthetics.

After 12 months, patients were invited for a follow-up examination. No pathological changes were found in patients who underwent dental implantation. One patient after

sinus lifting with one-stage implantation and two patients after sinus lifting with delayed implantation had dental implants removed several months after prosthetics due to their instability and the development of peri-implantitis.

Thus, summing up the results of the implant treatment of patients

In the second group, we received the following results: 42 implants that were installed without sinus lifting were successfully integrated and have been functioning for over a year. Three out of 54 implants installed simultaneously with sinus lifting were lost due to the development of peri-implantitis within a year after the operation, the remaining 51 implants are functioning successfully. Patients who underwent sinus lifting with delayed implantation were scheduled to have 28 implants. But, due to the development of complications after sinus lifting, 22 implants were installed, two of which were rejected 3 months after prosthetics. 20 implants have been successfully integrated and have been functioning for over a year.

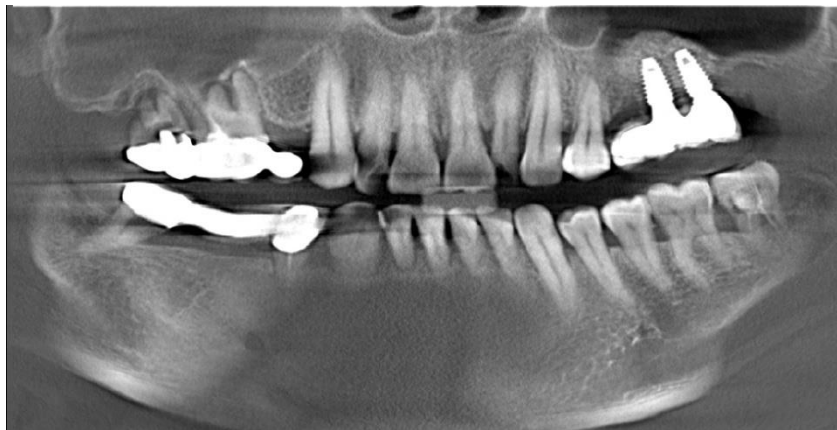


Fig. 5. OPTG of patient K, born in 1978, 6 months after surgery, sinus lifting with simultaneous implantation.

Shown in Fig. 5 OPTG defines a DIO dental implant placed in the position of tooth 26-27. A weak shadow of the bone graft material is visualized around the implant.

When viewed after 7 days, the operating area is normal, the sutures are consistent. Removal of stitches.

At the follow-up examination three months later, the patient had no complaints.

Clinical and X-ray examination revealed no complications.

After six months, there are no complaints either. Clinical examination and X-ray examination revealed no complications (Figure 3).

Referred to an orthopedic dentist for further prosthetics. After 12 months, the patient was invited for a follow-up examination. No complaints.

Results of implant treatment in patients of the second group with preliminary surgical debridement of the maxillary sinus

In our observations, all patients who underwent surgical treatment of sinusitis subsequently required elevation of the maxillary sinus floor with one-stage or delayed implantation. The need for bone augmentation was not due to the debridement of the sinus, but the course of the sinus lift operation depended on the method of preliminary.

Closed sinus lifting, in patients with preliminary combined endoscopic sinusitis, was performed without any deviations from the protocol. Open sinus debridement significantly affected the subsequent sinus lifting protocol. These patients always had an extensive bone defect in the anterior sinus wall, as well as gross fibrous degeneration of soft tissues.

Despite the difficulties of working with the mucous membrane, perforation of the mucous membrane was observed only in 3 cases in patients who underwent sinus lift with delayed implantation.

Bleeding from bone and soft tissues was also noted among intraoperative complications in patients of this group.

The course of the early postoperative period did not differ from that in patients of the first and control groups. However, we noted that in patients with a history of open sinusotomy, postoperative edema and stasis of soft tissues persisted longer, due to scarring and impaired venous and lymphatic outflow. Reactive postoperative inflammation lasted 7-14 days and was safely resolved against the background of conservative antibacterial and anti-inflammatory therapy

Complications in the early postoperative period were observed in two out of four patients in whom perforation was detected intraoperatively. In each of these observations, a clinic of serous sinusitis developed, which could be stopped by conservative methods of treatment. Postoperative hematoma was observed in 10 patients from this group of observations.

Three months later, during an interim examination of patients after sinus lifting with immediate implantation, in one case, the implant plug was exposed. This patient underwent replacement of the plug with a healing cap. Examination of patients after sinus lifting with delayed implantation revealed no pathology.

6 months after the operation, according to the standard prosthetics protocol on dental implants, all patients who underwent sinus lift with one-stage dental implantation received healing abutments. X-ray examination in one patient revealed partial exposure of the implant into the lumen of the VSP, however, without reactive changes in the mucous membrane of the sinus around, in other cases no pathology was revealed, all patients were referred for further prosthetics.

Thus, summing up the results of the implant treatment of patients of the second group (with preliminary surgical debridement of the maxillary sinus), we obtained the following result: all 95 planned implants were installed and have been successfully functioning for more than a year.

Below is a clinical example of implantological treatment of a patient with preliminary surgical debridement of the maxillary sinus.

Patient K., 30 years old, outpatient card No. 502.

Complaints: absence of chewing teeth on the upper jaw on the right

From the anamnesis of the disease: Teeth 16,17,15 were removed due to exacerbation of chronic periodontitis with varying frequency within 3 years. The patient had a history of chronic odontogenic maxillary sinusitis (Fig. 6), for which she was operated twice, 6 months apart, in the ENT department.

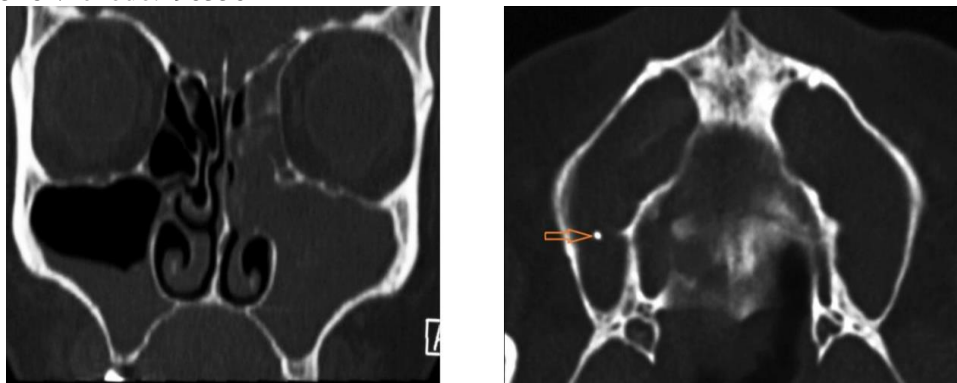


Figure: 6.
Fragments of
MSCT of patient
K., born in 1980

On the MSCT fragments shown in Figure 5, it is noted: curvature of the nasal septum, diffuse thickening of the mucous membrane of the upper part of the upper part on the right, a hyperintense shadow measuring 2 * 2 mm, irregularly shaped in the bay of the right upper part. Total darkening of the left VChP, block of the anthrochonal fistula on the left.

The first operation a year ago: endoscopic bilateral sinusotomy through the middle nasal passage. However, a month after the operation, the patient again began to notice the clinical manifestations of CHD, and control MSCT 6 months later revealed the persistence of diffuse thickening of the mucous membrane in the right VJJ and the presence of a foreign body.

The first operation a year ago: endoscopic bilateral sinusotomy through the middle nasal passage. However, a month after the operation, the patient again began to notice the clinical manifestations of CHD, and control MSCT 6 months later revealed the persistence of diffuse thickening of the mucous membrane in the right VJJ and the presence of a foreign body.

A repeated endoscopic combined sinusitis was performed with additional access in the canine fossa. According to the patient, the postoperative period was uneventful. I did not notice the phenomena of VChS

External examination: The configuration of the face is not changed, the skin is clean, without visible pathology. Peripheral lymph nodes are not palpable.

Free nasal breathing. The opening of the mouth is not limited.

Examination of the oral cavity: The mucous membrane is pale pink, moderately moist, without visible pathology. Hygiene is satisfactory.

Local examination: Alveolar ridge in the area of missing teeth 15, 16 without visible pathology (6), width ~ 8 mm. Inter-alveolar height 11mm

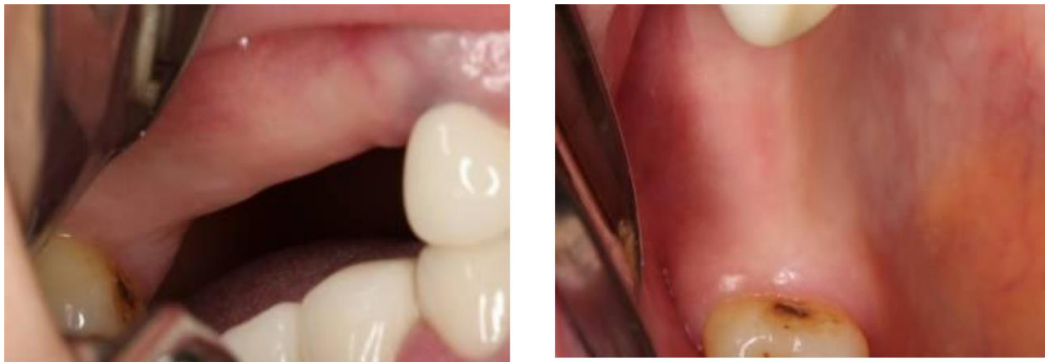

Figure: 6. Patient K, born in 1930 Photo of the oral cavity, upper jaw.

View from the vestibular (a) and occlusal (b) surfaces

Diagnosis: Secondary edentulous teeth 15,16,17.

According to the clinical examination and the results of the CBCT analysis, the patient was included in the second group of the study, there were no general contraindications to dental implantation. However, the height of the alveolar ridge is not sufficient for the installation of dental implants at the same time. It was decided to lift the bottom of the upper part of the patient's body by open sinus lifting with delayed installation of dental implants.

Operation: Open sinus lift

Under conditions of infiltration anesthesia Sol. Ultracaini DS forte (1: 100000) - 3.4 ml, the mucous membrane of the alveolar ridge was incised on the left in the position of teeth 15-17, the mucous-periosteal flap was detached, a bony window was formed along the anterolateral wall of the duodenum, an elevation of the sinus mucosa was performed (Figure 7)

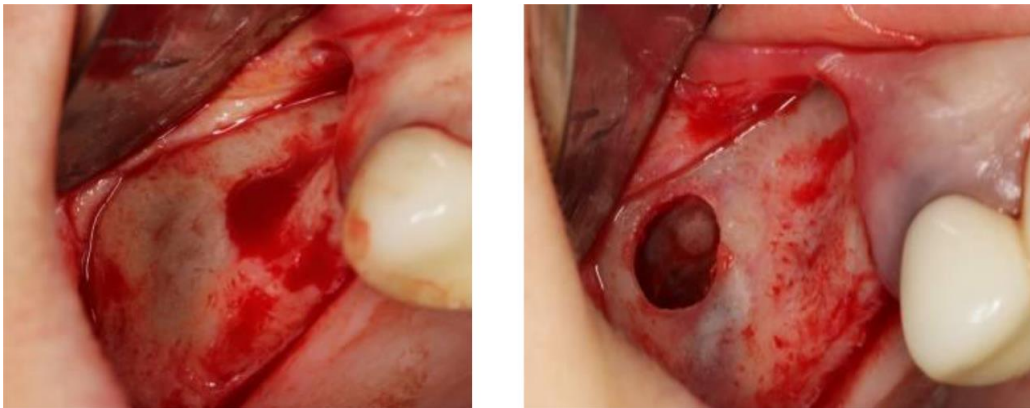


Fig. 7 a. Formed a bony window b. Detached muco-periosteal flap (a). Raised mucous membrane of the upper urinary tract (b)

The patient was fitted with dental implants with a diameter of 3.5 mm and a length of 10 mm in the positions of teeth 14, 16, 17. After 4 months, prosthetics based on dental implants was performed.

Thus, summing up the results of implantological treatment of patients in the control group (without pathological changes in the maxillary sinus), we obtained the following results: 24 implants that were installed without sinus lifting were successfully integrated and have been functioning for more than a year.

Conclusions

1. Dental implantation is possible in case of maxillary sinusitis without odontogenic foci of infection, other forms of sinusitis require preliminary sanitation.
2. The highest efficiency of implant treatment was noted in patients after surgical debridement of the maxillary sinus and amounted to 100; in patients with intact sinus - 96.4%
3. The developed scheme of the differentiated algorithm of preparation for dental implantation of patients with maxillary sinusitis reduces the risk of developing postoperative complications and improve the efficiency of dental implantation.

List of references

1. Anastasov A.N. Development of methods for restoring the volume of bone tissue of the alveolar process of the upper jaw in preparation for dental implantation: dis. ... Cand. honey. Sciences .: M., - 2002 .- 127s.
2. Baidik, O.D., Shilov, M.V., Dolgun, D.A., Logvinov S.V. Ultrastructural changes in the mucous membrane of the maxillary sinus in patients with odontogenic sinusitis // Bulletin of Siberian Medicine: scientific and practical journal. - 2009. - Volume 8, N 2. - S. 10-16.
3. Biryulev A.A. Modern aspects of prevention, diagnosis and complex treatment of chronic odontogenic perforated maxillary sinusitis in the early period of the disease: author. dis. ... Candidate of Medical Sciences: 14.01.14., 03.02.03 - M., 2012 .-- 25 p.
4. Gatal'skaya I.Yu. Treatment and prevention of traumatic sinusitis with zygomatic-maxillary fractures in conditions of concomitant injury: author. dis. ... Cand. honey. sciences. 14.01.14 - M., - 2010 .-- 24 p.
5. Ризаев Ж.А., Хазратов А.И. "Канцерогенное влияние 1,2 – диметилгидразина на организм в целом", Проблемы биологии и медицины, 116, №1, 269-272, 2020
6. Ризаев Ж.А., Хазратов А.И. «Состояние полости рта у больных раком толстой кишки». Актуальные проблемы современной медицины, 117, 1.1, 99, 2020
7. Ризаев Ж.А., Хазратов А.И. "Морфологические изменения слизистой полости рта при онкологических патологиях," Актуальные проблемы фундаментальной, клинической медицины и возможности дистанционного обучения" 115, 2020
8. Rizaev J.A., Khazratov A.I., Lisnichuk N.E., Olimjonov K.J., Reimnazarova G.Dj. Pathomorphological changes in the oral mucosa in patients with colon cancer "European Journal of Molecular & Clinical Medicine," 7, 7, 666-672, 2020
9. Rizaev J.A., Khazratov A.I. «Indicators of the microflora of the oral cavity in patients with colon cancer», Uzbek medical journal, 2, 50-55, 2020

10. Ризаев Ж.А., Хазратов А.И. «Макроскопическая картина слизистой оболочки полости рта у больных с онкологическими заболеваниями толстой кишки», Проблемы биологии и медицины, 122, 5, 114-117, 2020
11. Khazratov A.I., Rizaev Y.A. «Oral condition in patients with colon cancer» International Scientific and Practical Online Conference, Actual Problems of Fundamental, Clinical Medicine and Distance Learning, Opportunities," 137-138, 2020
12. Rizaev J.A., Khazratov A.I., «Цитоструктурное изменение слизистой оболочке полости рта при раке толстой кишки», Journal of Biomedicine and Practice, 6, 5, 2020
13. Качалиев Х.Ф., Кубаев А.С., Хазратов А.И., Мусинов О.Ш., Шавкатов П.Х. «Неотложная помощь при переломе скуловой кости и передней стенки гайморровой пазухи», Наука и образование сегодня, 60, 1, 44-48, 2021
14. Alisher I. Khazratov, Jasur A. Rizaev, Nataliya Ye. Lisnychuk, Gulsara Dj. Reimnazarova, Aziz S. Kubaev, Kamronbek J. Olimjonov. «Morphofunctional Characteristics Of The Oral Mucosa Of Experimental Rats In Experimental Carcinogenesis», European Journal of Molecular & Clinical Medicine, 8, 2, 227-234, 2021
15. Khazratov A.I., Rizaev J.A. «Comparative assessment of the clinical picture of the oral mucosa in patients with colon cancer», Proceedings of the 7 th International Scientific and Practical Conference, Tokyo, Japan, 41, 754-756, 2021
16. Yarmukhamedov B.N., Amanullayev R.A., Pulatova B.J. Assessment of possible risk of Dental implantation according to morphological criteria in patients with a somatic background pathology // American journal of research No. 7-8, 2020.